

REVISED

2:25 pm, Apr 05, 2018

The Inverse Injection Layering TECHNIQUE

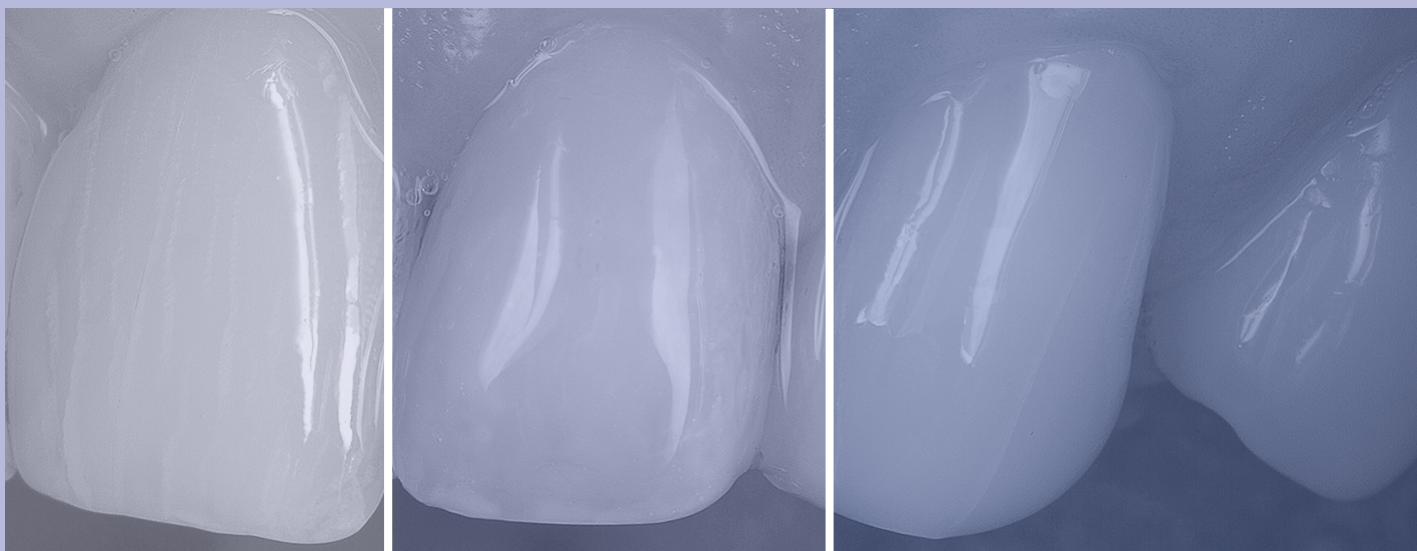
Douglas A. Terry, DDS, AAACD
John M. Powers, PhD
Markus B. Blatz, DMD, Dr med dent habil, PhD

Abstract

The concept of generating a variety of parts for different manufacturing solutions using an injectable molding technique has existed for more than a century. Since its evolution, injection molding has been used by designers and engineers for myriad applications with a host of materials, including glass, metals, confections, elastomers, and thermoplastic and thermosetting polymers to fabricate a variety of complex shapes with high dimensional precision. The advances in material science and adhesive technology have allowed this concept to be utilized with highly filled next-generation flowable systems. This first part of a planned two-part article provides a simplified, precise, and predictable method for developing natural esthetic composite restorations using this injectable concept with highly filled flowable materials.

Key Words: inverse injection layering technique, reversible, preparation-less, flowable resin composite, composite resin veneer

Although not a solution to all restorative challenges, this technique provides the patient and clinician with an alternative approach to various clinical situations.



Introduction

Continuing developments in adhesive technologies, the design of resin composite formulations, and innovative application techniques have revolutionized the delivery of minimally invasive direct resin composite restorations, thereby improving the practice of dentistry. In some cases, achieving optimal esthetic direct resin composite restorations requires utilizing complicated layering techniques that are dependent upon the clinician's skill and artistic ability. The inverse injection layering technique^{1,2} is a unique indirect/direct process of predictably translating a diagnostic wax-up or the anatomical form of the natural dentition of a pre-existing diagnostic model into composite restorations. It offers a simplified, precise, and predictable method for developing natural esthetic composite restorations, while reducing chair time. Although not a solution to all restorative challenges, this technique provides the patient and clinician with an alternative approach to various clinical situations.

Technique Benefits

Clinical Applications

There are a multitude of applications for this technique using a highly filled flowable resin composite. The clinical applications include:

- emergency repair of fractured teeth and restorations
- fabricating, modifying, and repairing prototypes and provisional restorations,^{3,4} composite restorations (Class III, IV, veneers)³ and pediatric composite crowns⁵
- resurfacing occlusal wear on posterior composite restorations
- resurfacing resin composite restorations (Class IV, V, veneers)
- establishing incisal edge length prior to esthetic crown lengthening⁴
- developing composite prototypes for copy milling⁴
- fabricating an implant-supported composite provisional
- restoring fractured or missing denture teeth
- managing spatial parameters during orthodontic treatment.

In addition, the inverse injection layering technique can be used to establish vertical dimension and alter occlusal schemes (anterior guidance and posterior disclusion) prior to restoring with final restorations.⁴ Furthermore, this noninvasive technique is an integral tool for enhancing communication between the patient and restorative team during treatment planning.³

Developing transitional resin composite restorations using the injectable technique is an excellent way to increase the patient's understanding of the planned clinical procedure and anticipated final result.⁶ Transitional composite prototypes allow the patient and restorative team to establish parameters for:

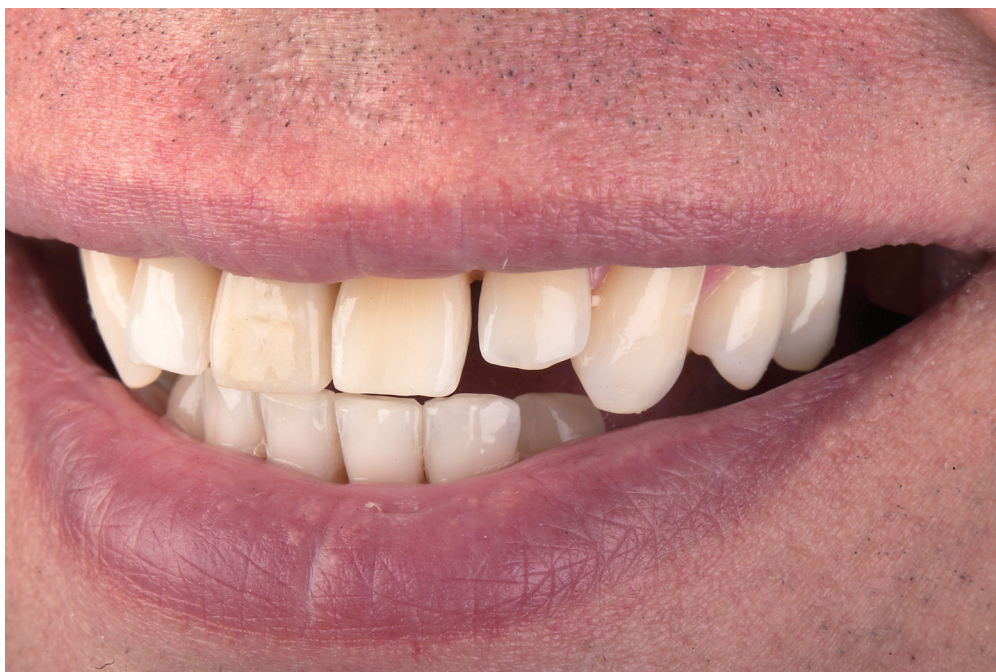- occlusal function⁷
- tooth position and alignment⁸
- restoration shape and physiologic contour⁹
- restorative material color and texture
- lip profile
- phonetics
- incisal edge position
- gingival orientation.

Other Advantages

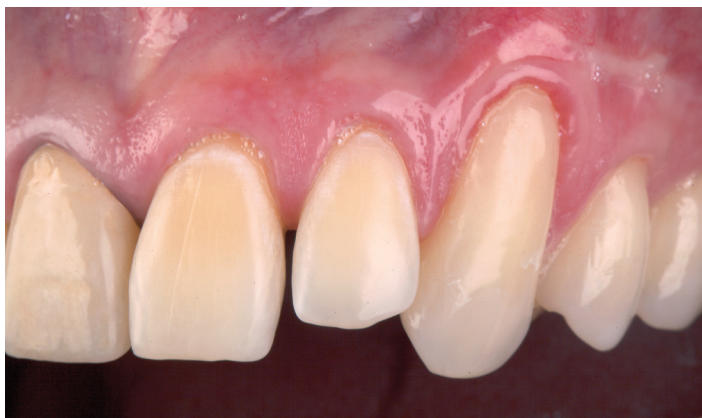This process also helps to decrease confusion and misunderstanding between the patient and the restorative team during the treatment-planning stage.⁶ The procedure can reduce the potential for patient dissatisfaction since it is reversible, can be performed without preparation, and allows the patient to approve the visual and functional result before the definitive restorations are fabricated. In addition, this simple procedure helps to regulate the dimensions of the preparation design, ensures uniform spatial parameters for the restorative material, and increases the potential for a more conservative preparation design.³

The injectable technique also can be used in the development and management of soft-tissue profiles and in the design of the definitive restoration.¹⁰⁻¹³ The clinician and technician can use this reversible and preparation-less technique as a guide for developing a pre-approved functional and esthetic final restoration. This process aids the clinician and technician during the design and fabrication of the definitive restoration by providing a visual for the patient and the restorative team as well as the ability to communicate extensive details concerning the treatment plan and the fabrication of final restorations.¹⁴ In some cases, these transitional restorations can be worn for months or even years by patients during long-term interdisciplinary rehabilitation.³

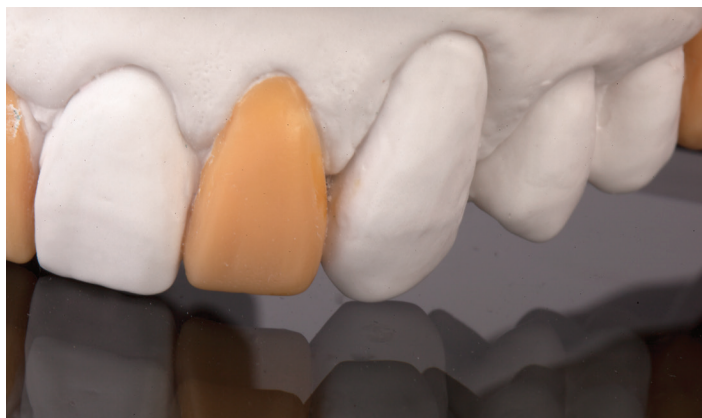The inverse injection layering technique can be performed intraorally without anesthesia in some clinical situations. A clear vinyl polysiloxane (VPS) impression material is used to replicate the diagnostic wax-up or the anatomical form of the natural dentition of a pre-existing diagnostic model. The clear matrix can be placed intraorally over the prepared or unprepared teeth and used as a transfer vehicle for the flowable resin composite to be injected and cured.



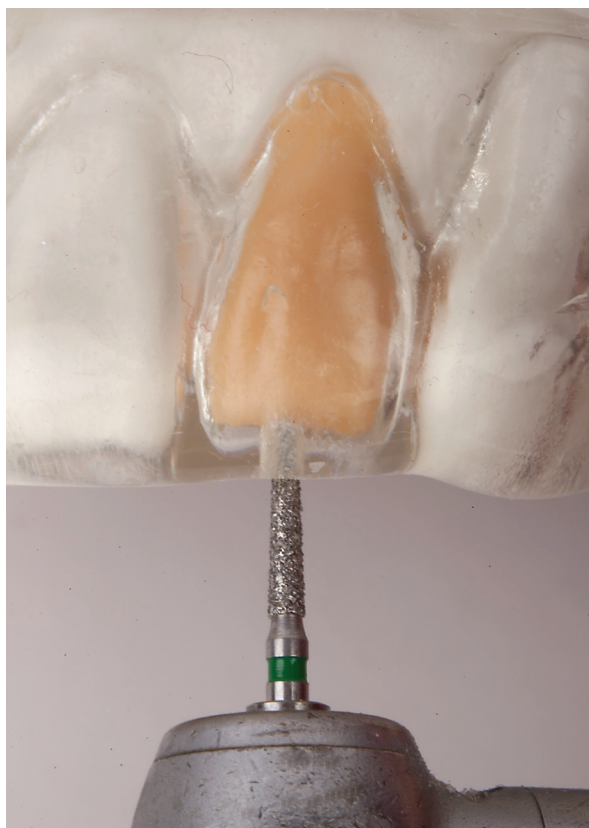Preoperative facial view of the maxillary anterior segment. This 47-year-old patient presented with cosmetic concerns regarding his smile. He requested a conservative esthetic enhancement without orthodontic treatment.



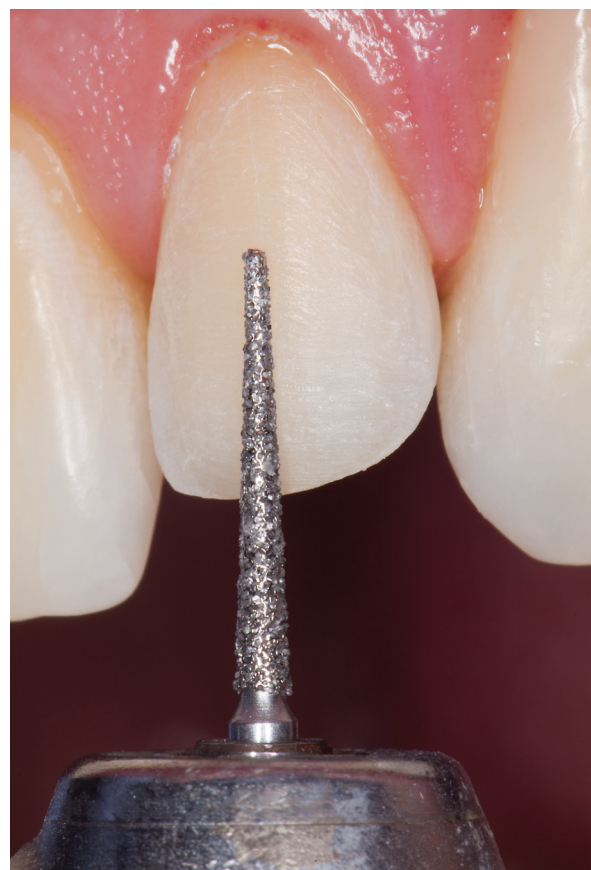Clinical examination and evaluation revealed a diastema on the mesial of the maxillary left lateral incisor with gingival recession on the maxillary left central, lateral, and canine.



Development of a diagnostic wax-up that established new esthetic and functional parameters for the definitive restoration, which would be completed after connective tissue grafting on the maxillary left quadrant. (Laboratory work by Jungo Endo, RDT)

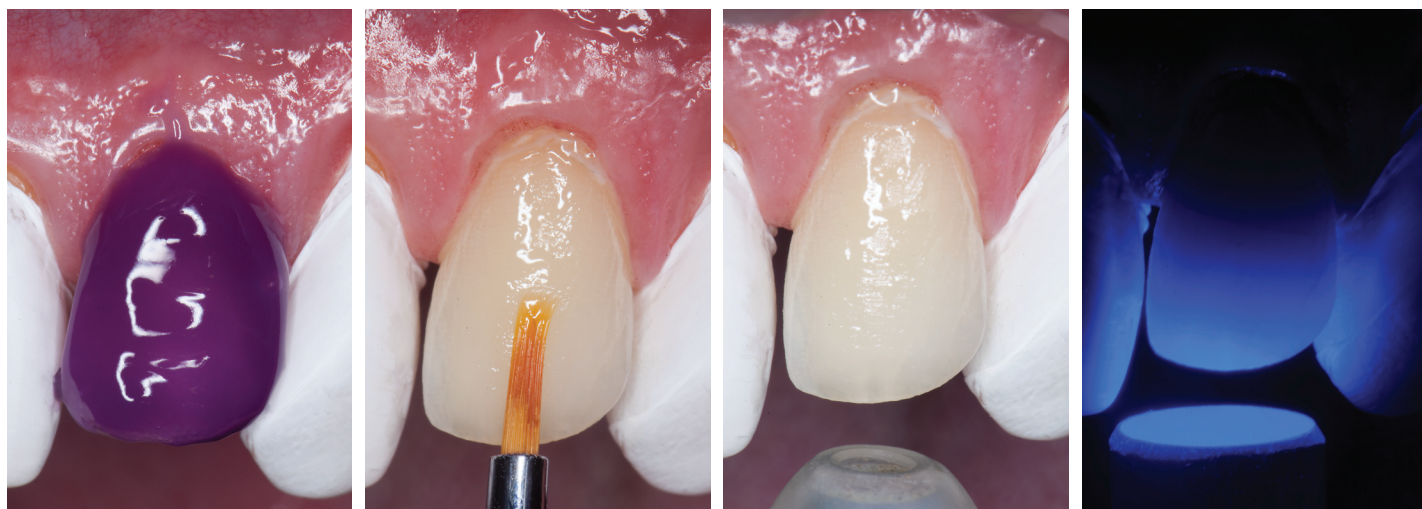

A clear VPS matrix was fabricated to replicate the diagnostic wax-up using a nonperforated tray. A small opening was made above the lateral incisor that was to be restored using a tapered diamond bur (6847, Brasseler USA; Savannah, GA). It is important to clean the internal surfaces with a micro brush to prevent silicone debris from becoming incorporated into the flowable material.

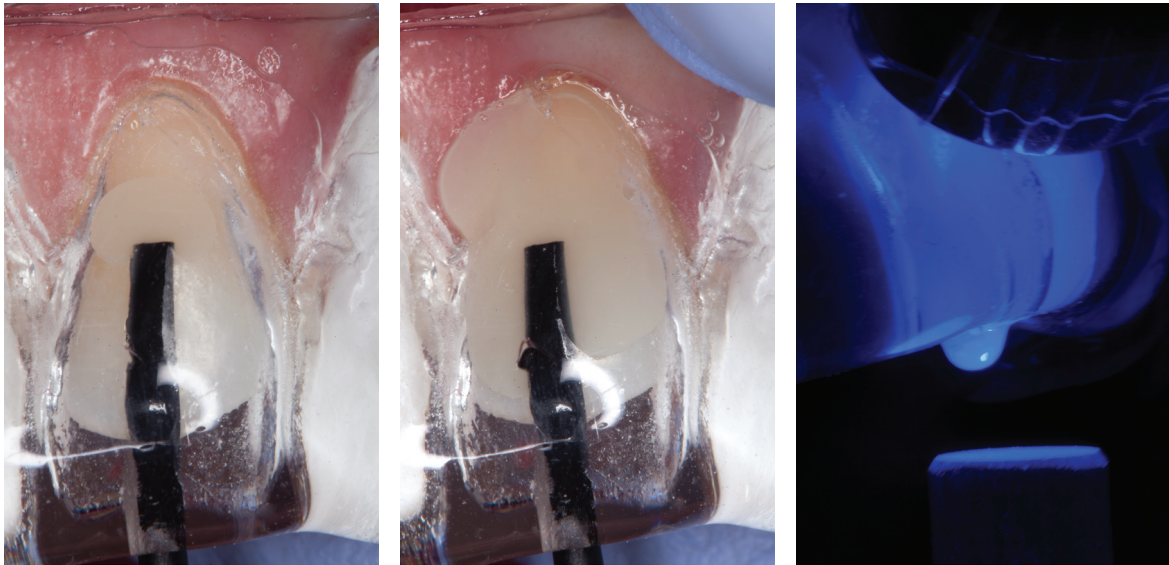


The primary factors to consider prior to the veneer preparation of any tooth include anatomic variations in enamel thickness according to tooth, and location on the tooth and the definitive restorative dimension.¹ The preparation of this lateral incisor included a conservative intraenamel facial reduction of 0.2 mm, a supragingival chamfer of 0.1 mm, and an incisal overlap chamfer of 0.2 mm with all line angles and corners smoothed and rounded to improve resin adaptation and reduce the potential for stress concentrations in the restoration.

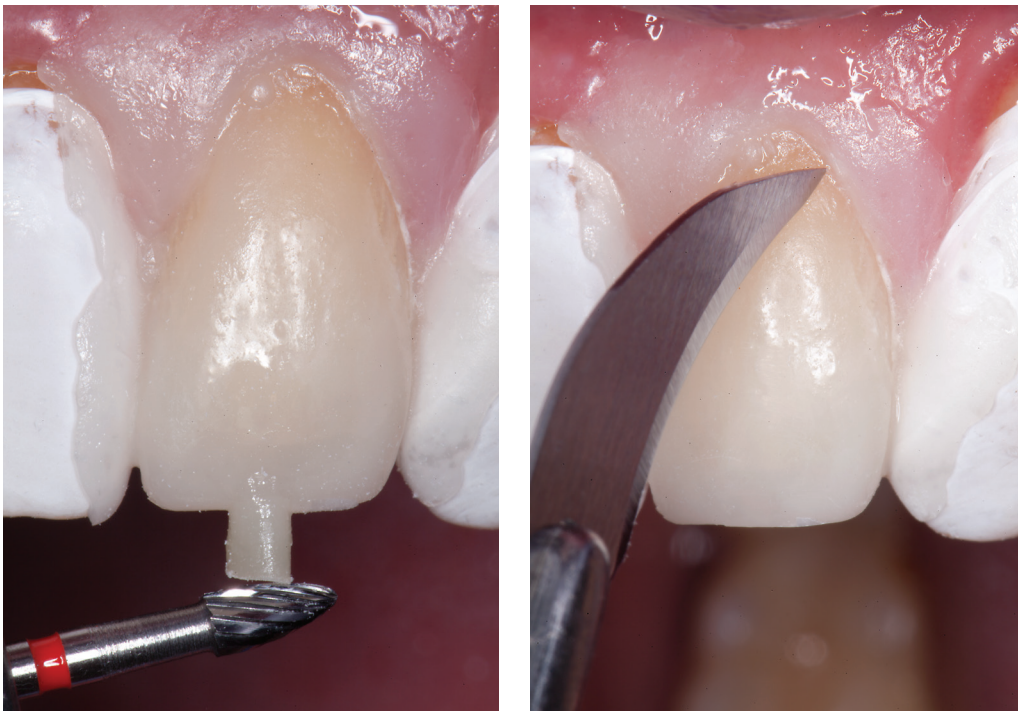The primary factors to consider prior to the veneer preparation of any tooth include anatomic variations in enamel thickness according to tooth, and location on the tooth and the definitive restorative dimension.



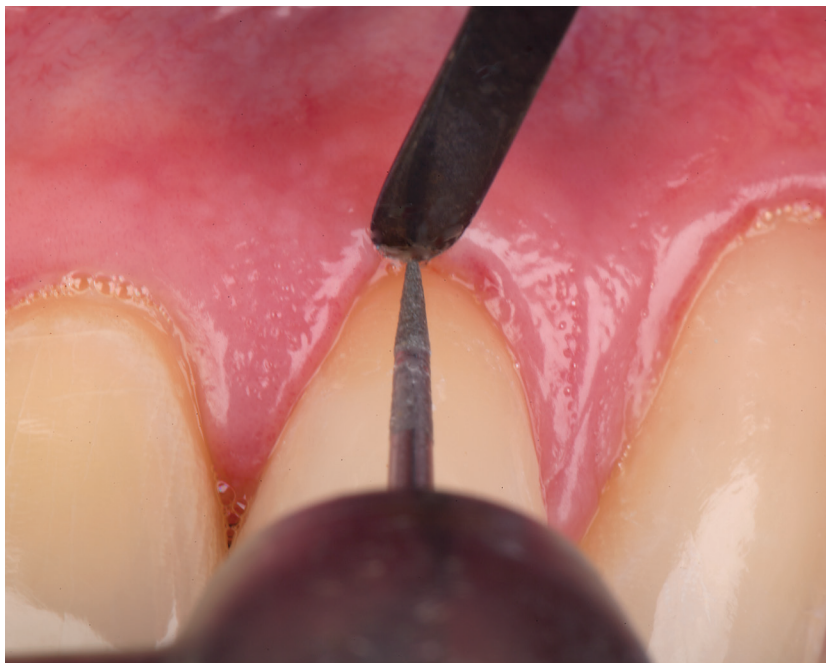Before adhesive surface preparation, each tooth was separated by applying sterilized Teflon tape on the adjacent teeth. A 37.5% phosphoric acid semi-gel (Gel Etchant, Kerr Restoratives; Orange, CA) was applied to the enamel surface for 30 seconds, rinsed with water for 5 seconds, and gently air-dried. A universal adhesive (G-Premio Bond, GC America; Alsip, IL) was applied to the enamel surface and allowed to sit for 10 seconds, air-dried for 5 seconds, and light-cured for 10 seconds using an LED curing light (Silverlight, GC America).



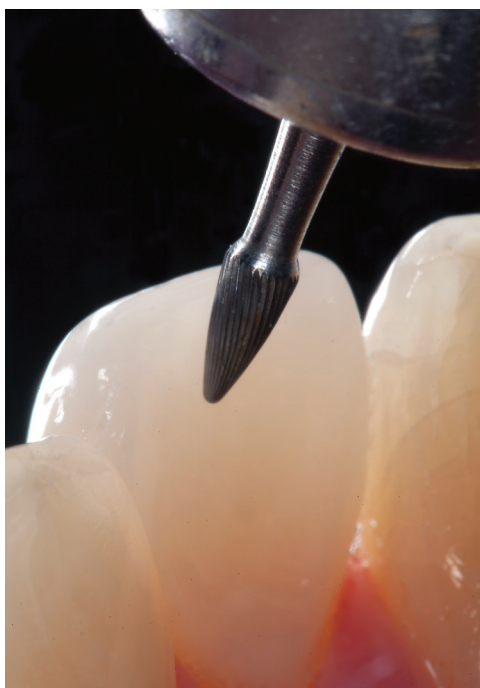The clear silicone matrix was placed over the maxillary arch and an opacous flowable resin composite (shade A-1, G-aenial Universal Flo, GC America) was injected through a small opening above the preparation, followed by a B-1 shaded flowable resin composite (the inverse injection layering technique). The resin composite mix was cured through the clear resin matrix on the incisal, facial, and lingual aspects for 40 seconds each.



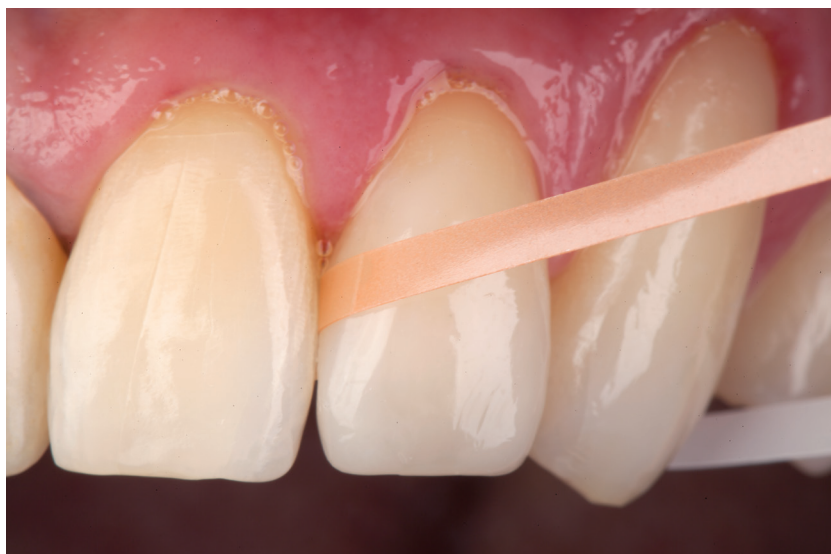When removing the matrix, it is important to gently flex the silicone material over the composite sprue to prevent the matrix from tearing. The incisal composite sprue was removed with a 12-fluted tapered finishing bur) (Neumeyer H274) and the excess polymerized resin composite was removed with a scalpel blade (#12 Bard-Parker, BD Medical; Franklin Lakes, NJ).



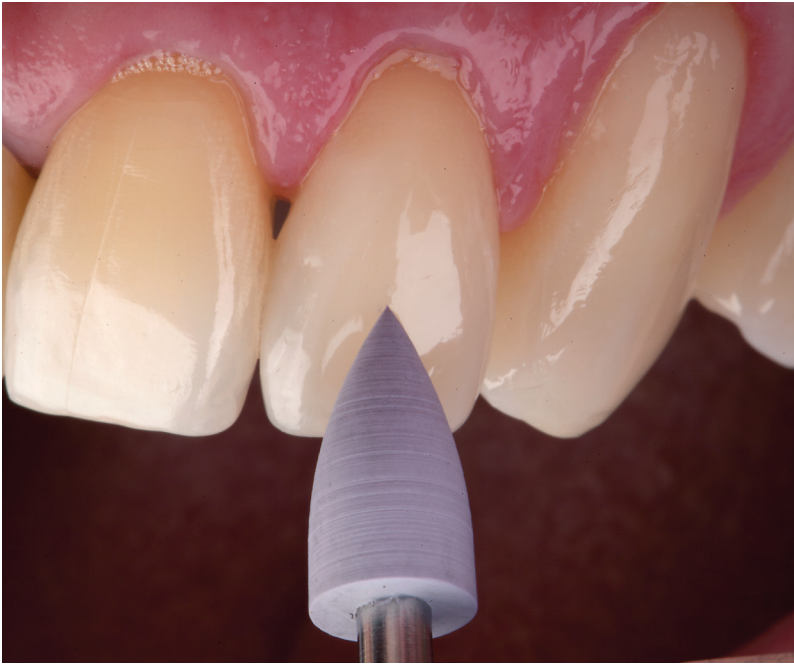The gingival tissue was retracted with a gingival protector (8A, Hu-Friedy; Chicago, IL), and the tooth-resin composite interface was finished using a tapered finishing diamond (DET finishing bur series, Brasseler).



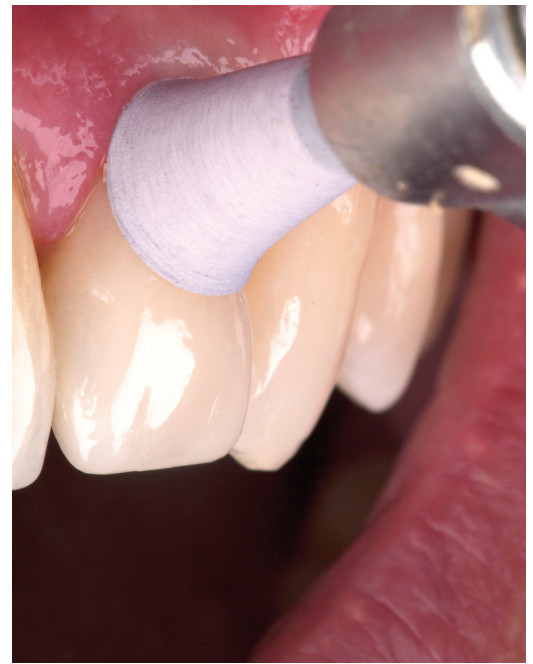The lingual tooth-resin composite interface was finished using a white-banded 30-fluted tapered finishing bur (Neumeyer H274) that conformed to the appropriate curvature of the tooth surface and composite restoration.



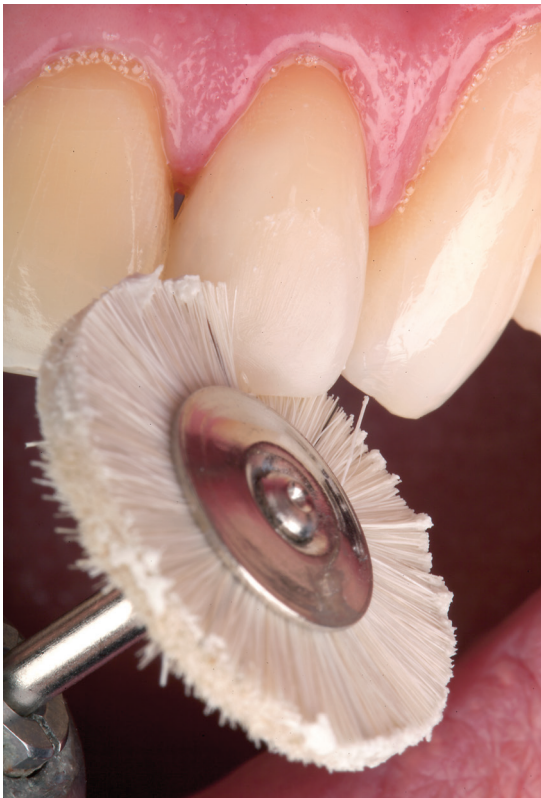The proximal surfaces and contours were smoothed with finishing strips used sequentially according to grit, ranging from fine to extra-fine (ET Composite Strips, Brasseler).



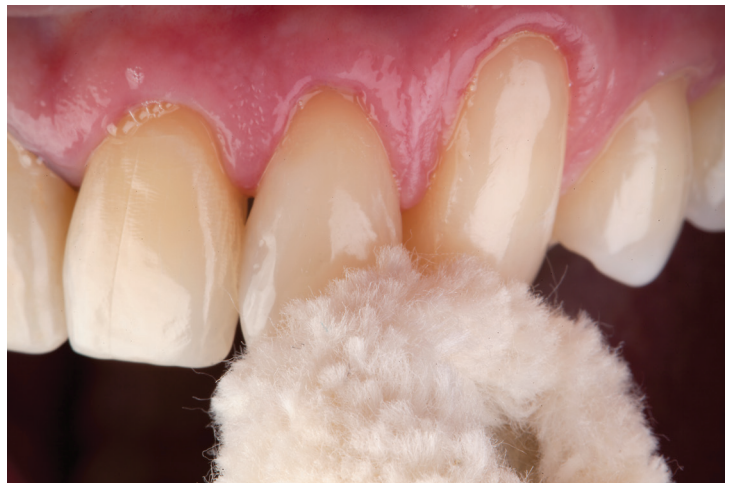The facial surface was polished with a silicone point (ET Illustra, Brasseler).



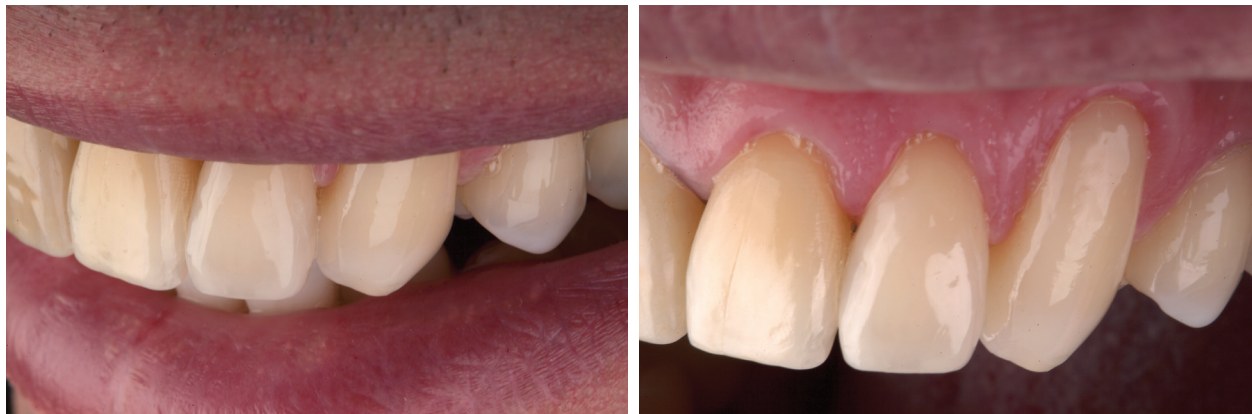The gingival region was polished with a silicone hollow cup (ET Illustra, Brasseler).



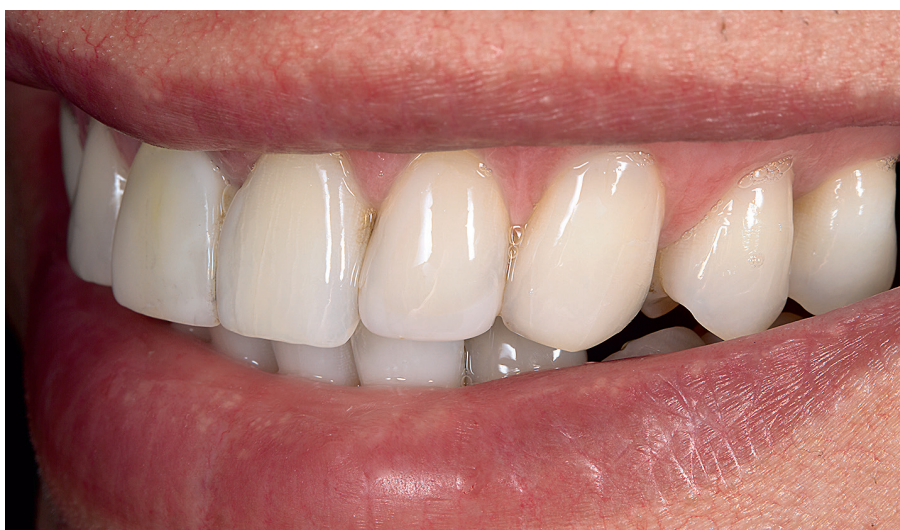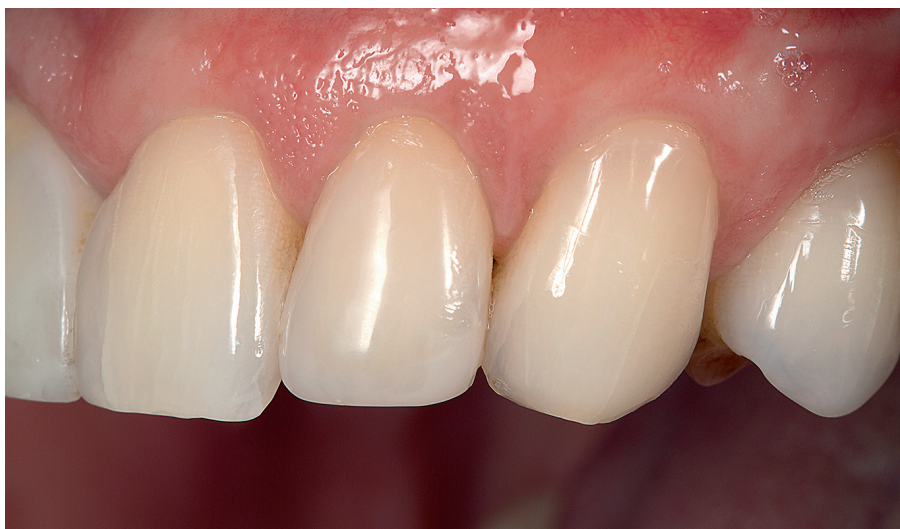A goat-hair wheel (Soft Goat Hair Brush, Brasseler) and diamond polishing paste were used to further refine the surface luster of the resin composite.



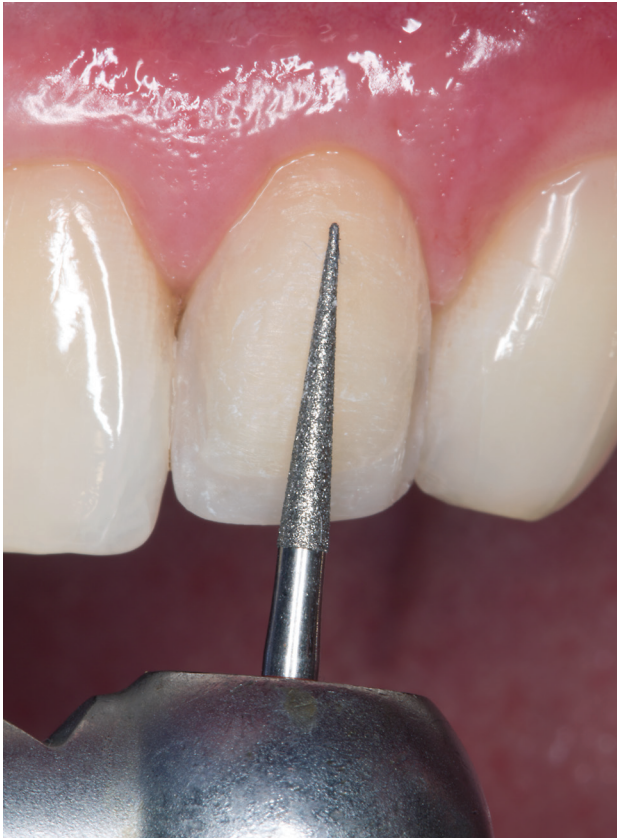High surface gloss was accomplished with a dry cotton buff (Cotton Buff Wheel, Brasseler) applied with an intermittent staccato motion.



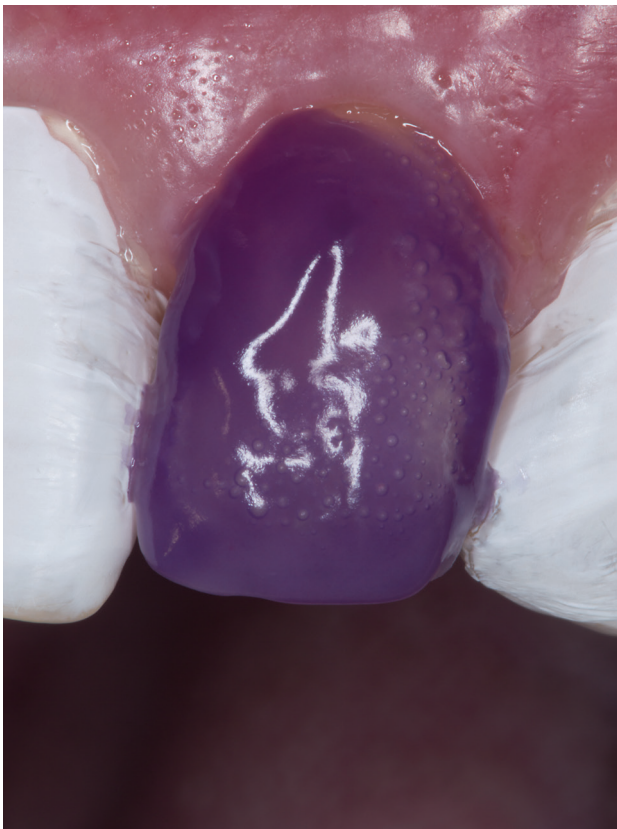The completed resin composite veneer with optimal anatomical form. The inverse injection layering technique allowed harmonious proportions of the composite restoration and the surrounding dentition to be established. The composite veneer established the optimal esthetic parameters for a natural smile.



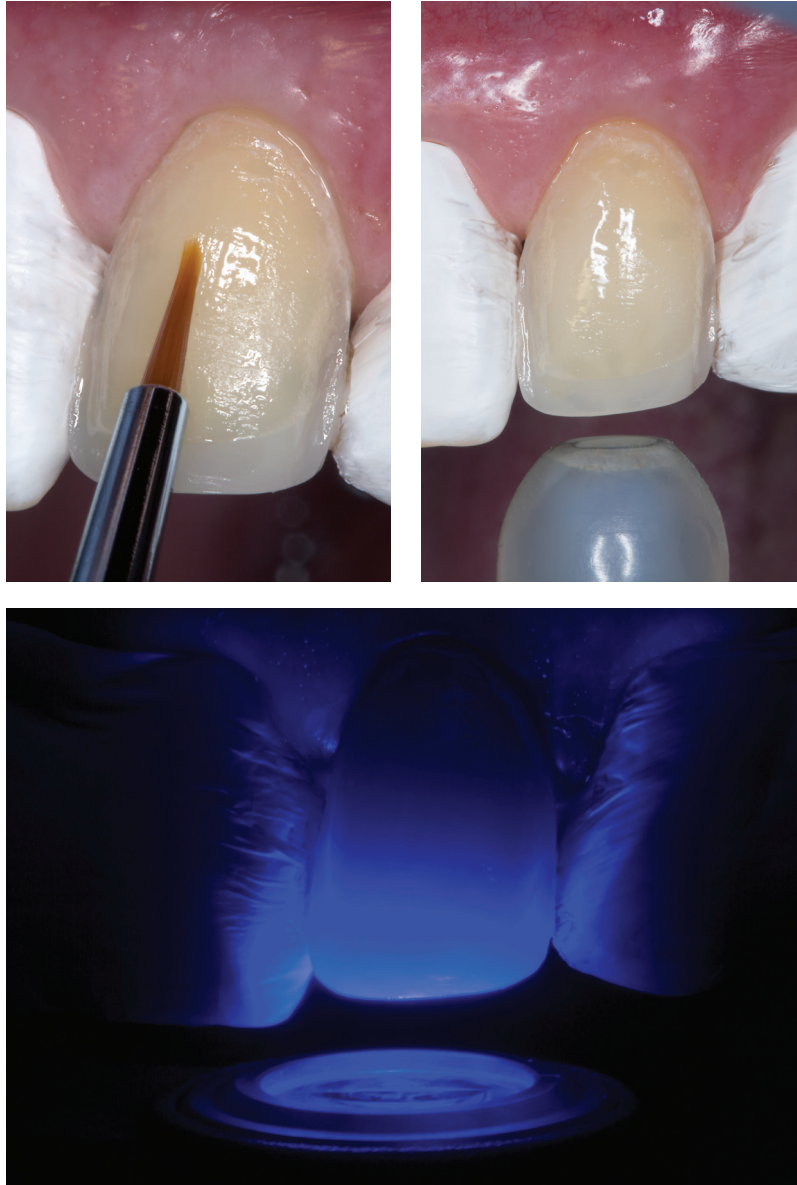
A one-year follow-up image after completion of the connective tissue grafting procedure.
(Periodontal surgery by Wesam Salha, DDS, DMD. For more information on the surgical procedure see Esthetic and Restorative Dentistry: Material Selection and Technique, 3rd edition.)



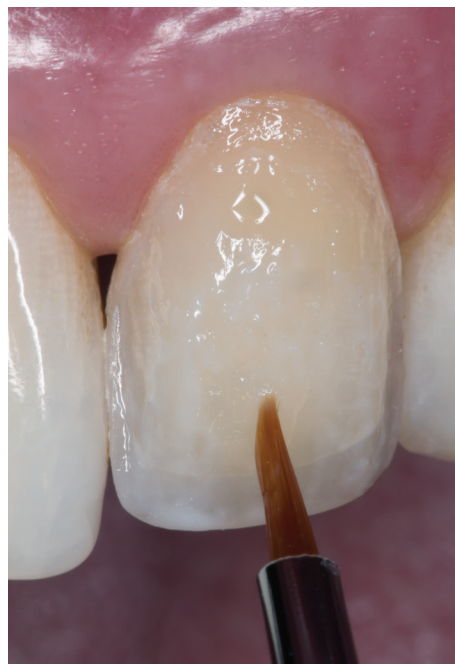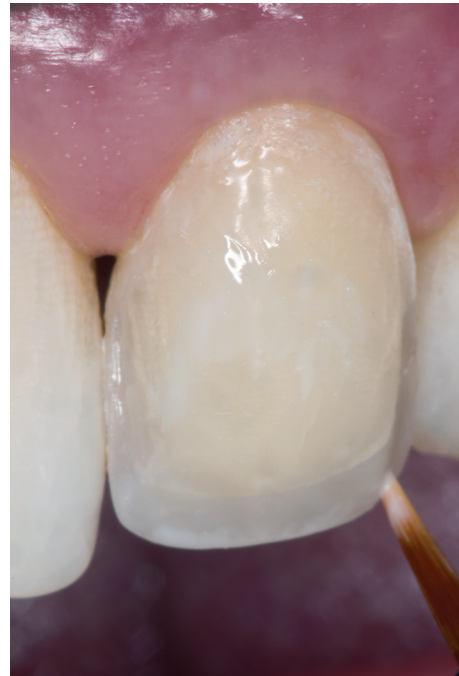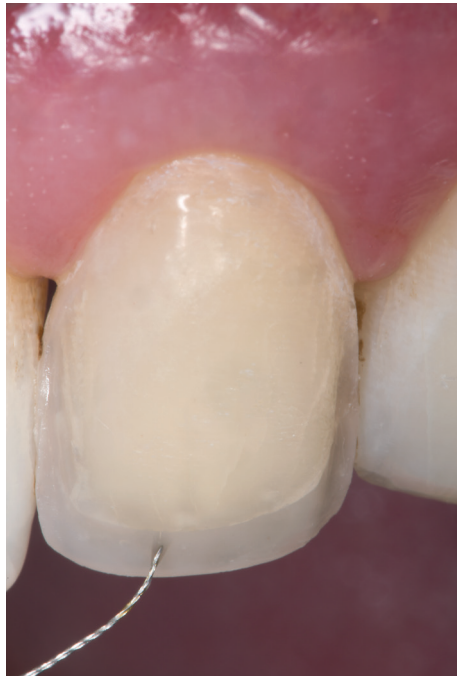After maturation of the soft tissue, the definitive restoration was completed by using a composite cut-back technique. The artificial enamel layer of the composite resin veneer was removed, and a corrugated 0.3-mm deep chamfer was placed around the entire margin with a long, tapered diamond (DET 9, Brasseler).




The entire composite surface was etched with 37.5% phosphoric acid (Gel Etchant) for 15 seconds and rinsed for 5 seconds. Etching of the existing composite cleans the surface.



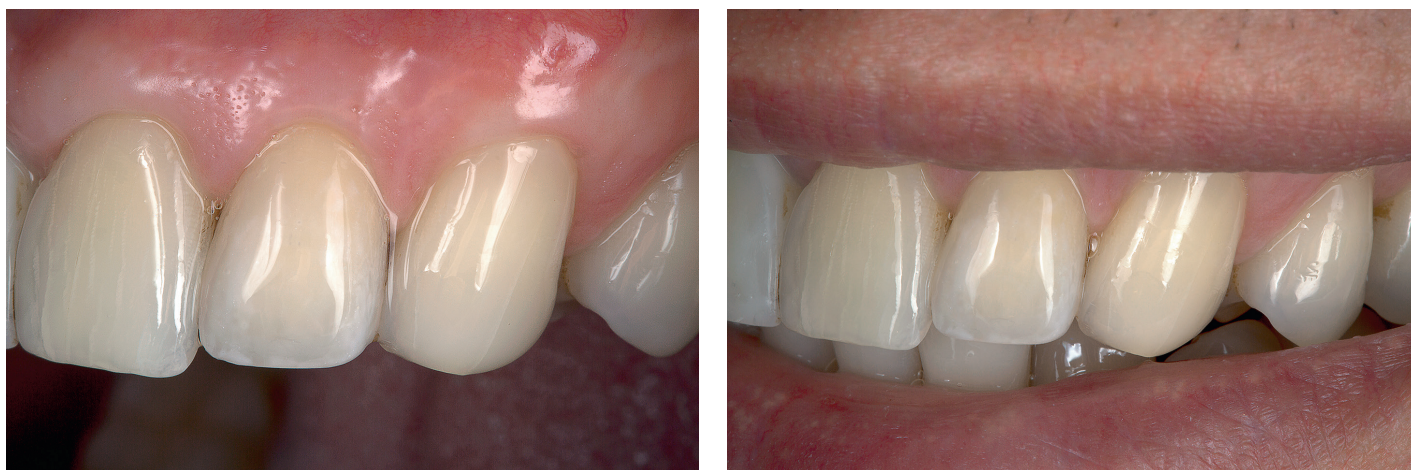Silane (G-Multi Primer, GC America) was applied to the composite surface and lightly air-dried. An adhesive (G-Premio Bond, GC America) was applied to the composite surface and allowed to sit for 10 seconds, air-dried for 5 seconds, and light-cured for 10 seconds using an LED curing light (The Light, GC America).



Internal characterization was performed according to the appearance of the contralateral tooth utilizing a shade map. A diluted gray tint (Renamel Creative Color, Cosmedent; Chicago, IL) was placed along the incisal edge and proximal regions with a size 08 endodontic file (08 K-Flex Files, Kerr Endodontics; Orange, CA) and light-cured for 40 seconds. A diluted white tint (Renamel) was placed along the incisal edge, proximal regions, and in the body with a small-tipped sable brush and light-cured for 40 seconds to stabilize the color and prevent mixing of the tints. A diluted yellow tint (Renamel) was placed at the cervical and in the incisal one-third with a small-tipped sable brush and light-cured for 40 seconds. It is the color variation from these modifiers and tints that creates the three-dimensional effect and the nuances within the incisal edge.



A new clear silicone matrix fabricated after the connective tissue surgical procedure was placed over the anterior segment of the maxillary arch, and a clear translucent shade flowable resin composite (JE, G-aenial Universal Flo) was injected through a small opening over the artificial dentin layer. The resin composite was light-cured through the clear resin matrix on the facial and incisal aspect for 40 seconds each.



The completed composite resin veneer with an ideal anatomical form and color. Note the nuances in the incisal edge created by using the composite cut-back technique.

Summary

Future clinical applications of the inverse injection layering technique may provide clinicians and technicians with alternative approaches to various clinical situations while allowing them to deliver improved and predictable dental treatment to their patients. Although the long-term benefits of this technique remain to be determined, the authors' clinical results in the past 11 years and the supporting empirical data for next-generation nanocomposite flowable composites are extremely promising.¹⁵⁻¹⁷ It is important to remember that various commercial flowable composites have different compositions and, therefore, exhibit variations in mechanical, physical, and optical properties. When selecting a material for a particular clinical situation it is imperative to evaluate the individual mechanical properties of these materials to determine whether they are equal or superior to those of alternative materials.

The planned second part of this two-part article will offer a description of the inverse injection layering technique, illustrating several applications using a highly filled flowable composite resin and how it can be used to develop anatomical spatial parameters and natural esthetics during interdisciplinary treatment.

Acknowledgment

This article was adapted with permission from the primary author's book Restoring with Flowables, Quintessence Publishing, Chicago; 2016.

References

1. Terry DA. Restoring with flowables. Hanover Park (IL): Quintessence Pub.; 2016.
2. Terry DA, Geller W. Esthetic and restorative dentistry: material selection and technique, 3rd ed. Hanover Park (IL): Quintessence Pub.; 2018.
3. Terry, DA. Developing a functional composite resin provisional. *Am J Esthet Dent.* 2012;2(1):56-65.
4. Terry DA, Powers JM. A predictable resin composite injection technique, part 1. *Dent Today.* 2014;33(4):96,98-101.
5. Terry DA, Powers JM, Mehta D, Babu V, Usha HL, Santosh A, Kida Y, Wakatsuki H. A predictable resin composite injection technique, part 2. *Dent Today.* 2014;33(6):80-5.
6. Terry DA, Leinfelder KF, Geller W. Provisionalization. In: *Aesthetic & Restorative Dentistry: Material Selection & Technique.* Houston, TX: Everest Publishing Media; 2009.
7. Heymann HO. The artistry of conservative esthetic dentistry. *J Am Dent Assoc.* 1987 Dec;Spec No:14E-23E.
8. Gürel G. The science and art of porcelain laminate veneers. Berlin: Quintessence Pub.; 2003.
9. Baratieri LN. Esthetics: direct adhesive restoration on fractured anterior teeth. São Paulo: Quintessence Pub.;1998.
10. Donovan T, Cho G. Diagnostic provisional restorations in restorative dentistry: the blueprint for success. *J Can Dent Assoc.* 1999;65(5):272-5.
11. Preston JD. A systemic approach to the control of esthetic form. *J Prosthet Dent.* 1976;35:393-402.
12. Yuodelis RA, Faucher R. Provisional restorations: an integrated approach to periodontics and restorative dentistry. *Dent Clin North Am.* 1980;24(2):285-303.
13. Saba S. Anatomically correct soft tissue profiles using fixed detachable provisional implant restorations. *J Can Dent Assoc.* 1997;63(10):767-70.
14. Terry DA, Geller W. Esthetic and restorative dentistry: material selection and technique, 2nd ed. Hanover Park (IL): Quintessence Pub.; 2013.
15. Karaman E, Yazici AR, Ozgunaltay G, Dayangac B. Clinical evaluation of a nanohybrid and a flowable resin composite in non-carious cervical lesions: 24-month results. *J Adhes Dent.* 2012;14:485-92.
16. Torres CRC, Rego HM, Perote LC, Santos LF, Kamozaiki MB, Gutierrez NC, Di Nicolo R, Borges AB. A split-mouth randomized clinical trial of conventional and heavy flowable composites in Class II restorations. *J Dent.* 2014;42:793-9.
17. Sumino N, Tsubota K, Toshiki T, Shiratsuchi K, Miyazaki M, Latta M. Comparison of the wear and flexural characteristics of flowable resin composite for posterior lesions. *Acta Odontol Scand.* 2013;71:820-7. **jCD**



Dr. Terry is an adjunct professor in the Department of Restorative Sciences at the University of Alabama at Birmingham, and Professor Emeritus in the Department of Conservative Dentistry and Endodontics at the V.S. Dental College & Hospital, Rajiv Gandhi University of Health Sciences in Bangalore, India. He maintains a private practice in Houston, Texas.




Dr. Powers is a clinical professor of oral biomaterials in the Department of Restorative Dentistry and Prosthodontics at the University of Texas School of Dentistry at Houston.



Dr. Blatz is a professor of restorative dentistry and chair of the Department of Preventive and Restorative Sciences at the University of Pennsylvania School of Dental Medicine in Philadelphia, Pennsylvania.


Disclosures: The authors did not report any disclosures.




Highly Esthetic Highly Simplified

ESTELITE OMEGA


MASTER ESTHETIC RESTORATIONS WITH JUST 11 SHADES



Superior shade-blending and esthetics thanks to our spherical filler technology.



Ideal handling for polychromatic layering of tooth anatomy.



Customize restorations with Estelite Color tints and opaquers.



Try **ESTELITE OMEGA** for

FREE

Promo Code:
OMDTN11

Call **1-877-378-3548** or visit **EsteliteOmega.com** to request a sample*

* Limit 1 FREE Estelite Omega sample per Dentist. New users of Estelite Omega in the U.S. only. Offer valid until 1/31/2018 or while supplies last.
©2017 Tokuyama Dental America Inc. | 10111702

